

## Pulmonary Function Tests

Authors: Scott Hagan, Tyler Albert

### Definitions of selected tests:

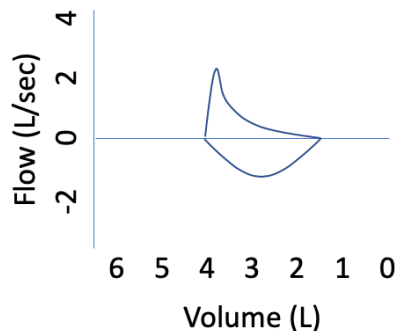
- PFTs consist of spirometry, lung volumes, DLCO and the flow-volume loop.
- Spirometry: measures FEV1 (forced expiratory volume in 1 second), FVC (forced vital capacity), SVC (slow vital capacity), and the FEV1/FVC or FEV1/SVC ratios to diagnose airflow obstruction. Bronchodilators can be administered to assess for reversibility of airflow obstruction.
- Lung Volumes: measures TLC (total lung capacity), RV (residual volume after full exhalation), FRC (functional residual capacity, volume remaining at the end of tidal exhalation). Used to diagnose restriction, hyperinflation, and air trapping.
- DLCO (Diffusion Capacity for Carbon Dioxide): measures gas exchange across alveolar-capillary barrier, serving as a marker for functional surface area, often corrected for anemia
- Flow-volume loop: visual representation of airflow from full inspiration and full expiration

### Case

A 65-year-old man presents with progressive dyspnea with exertion and the following pulmonary function tests:

		Actual	Predicted	% Predicted	Post-BD	Post-BD % Change
Spirometry	FEV1	1.2 L	3.70 L	32%	1.30 L	8%
	FVC	2.1 L	4.95 L	42%	2.2 L	5%
	FEV1/FVC	0.57 L	N/A	N/A		
Lung Volumes	TLC	4.0 L	6.2 L	65%		
	RV	1.5 L	2.1 L	71%		
	DLCO corr	5	33	15%		

Flow-Volume Loop:



### Stepwise Approach to Interpretation of PFTS:

- (1) Look at spirometry. Is there obstruction? Suggestion of restriction?
- (2) Look at lung volumes. Is there restriction? Hyperinflation? Air-trapping?
- (3) Look at DLCO. Is there an isolated gas exchange disorder?
- (4) Look at flow-volume loop. Is there upper airway obstruction?

Look at spirometry. Is there obstruction?

- FEV1/FVC ratio  $< 0.70$  is diagnostic of airflow obstruction.
- Bronchodilator response (BDR) is (+) if FVC OR FEV1 increase by 200cc AND 12%.

- History (age of onset, atopy, smoking history), NOT (+) BDR, distinguishes asthma from COPD.

Look at lung volumes (or SVC). Is there restriction?

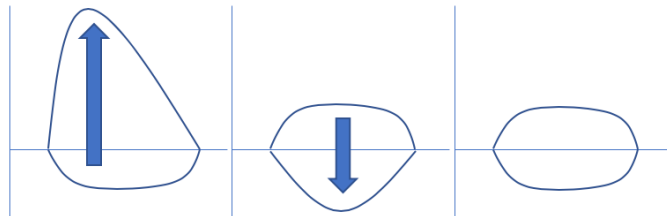
- Low TLC (< 80% predicted) is diagnostic of restriction.
- DDX is intra-parenchymal (interstitial lung diseases) versus extra-parenchymal (pleural diseases, chest wall disorders, diaphragmatic paralysis, extra-thoracic disorders, neuromuscular weakness).
- High TLC (> 120% predicted, a.k.a. hyperinflation) is often due to air-trapping (RV > 120% predicted) from emphysema or chronic asthma.

Look at DLCO. Is there an isolated gas exchange disorder?

- Abnormal DLCO suggests an abnormal surface area for gas exchange
- Abnormal DLCO with obstruction: suggestive of emphysema rather than asthma
- Abnormal DLCO with restriction: suggestive of intraparenchymal restrictive lung disease
- Abnormal DLCO without obstruction or restriction: pulmonary vascular diseases (e.g. idiopathic pulmonary hypertension)
- Normal DLCO with restriction: extraparenchymal disorder. Can obtain MIP (maximum inspiratory pressure), MEP (maximum expiratory pressure), and upright and supine PFTs to assess for a neuromuscular disorder.

Look at flow-volume loop. Is there upper airway obstruction?

- Scooped out appearance of expiratory flow is suggestive of air flow obstruction.
- In restrictive lung disease, the contour of the loop will be unchanged but loop size will be smaller (shorter x-axis because less lung volume and shorter y-axis because less flow)
- For variable flow-volume loops: picture the loop as an arrow pointing up (extrathoracic) or down (intrathoracic) to the affected area



Variable Extrathoracic Variable Intrathoracic Fixed Obstruction

### Back to Case

Our patient has (1) airflow obstruction (FEV<sub>1</sub>/FVC 0.57) with no bronchodilator response (FEV<sub>1</sub> and FVC changes < 200 cc & 12%), (2) restriction (TLC 65%), (3) parenchymal disease (DLCO 15%), and (4) flow-volume loop suggestive of a combined obstructive and restrictive process. A CT scan of the chest revealed combined pulmonary fibrosis and emphysema.

### Pearls

1. FEV<sub>1</sub>/FVC (airflow obstruction), TLC (restriction) and D<sub>L</sub>CO (emphysema, ILD, pulmonary vascular disease) are the most important PFTs for building a differential diagnosis.
2. Flow-loop patterns can catch variable extra-thoracic obstruction when PFTs are otherwise normal.
3. History, not BDR, distinguishes asthma from COPD.
4. DLCO can help to distinguish between intra- versus extra-parenchymal respiratory disorders.

### Resources:

1. Series ATS/ERS Task Force: Standardisation of lung function testing: Interpretative strategies for lung function tests. Pellegrino R, Viegi G et al. Eur Resp J 2005; 26: 948-968.